

# New use for Argyle trocar catheter: treatment of pelvic abscess following transvaginal ultrasound-directed follicle aspiration (UDFA)

G. NARGUND and J. PARSONS\*

Diana, Princess of Wales Centre for Reproductive Medicine, Academic Department of Obstetrics and Gynaecology, St George's Hospital Medical School, London, \*Department of Obstetrics and Gynaecology, King's College Hospital School of Medicine and Dentistry, London, UK

**KEYWORDS:** Pelvic abscess, Complication, Endometriosis, IVF, Drainage

## ABSTRACT

*This report describes the use of an Argyle trocar catheter for the drainage of pelvic abscesses following transvaginal ultrasound-directed follicle aspiration (UDFA) for oocyte collection. Three patients treated with this technique recovered uneventfully. We conclude that the use of an Argyle trocar catheter for colpotomy in the management of pelvic abscesses appears to be simple and effective.*

## INTRODUCTION

Oocytes for assisted conception are usually collected transvaginally by ultrasound-directed follicle aspiration (UDFA). It is a simple and effective technique. The incidence of abscess following transvaginal ultrasound directed follicle aspiration was reported to be 9% of all cases<sup>1</sup>. Acute pelvic inflammatory disease following UDFA is an infrequent complication, the reported incidence being 0.6%.<sup>2</sup> Prophylactic antibiotic therapy with or without needle drainage of the abscesses may not be effective<sup>3</sup>. Laparotomy for pelvic abscess is potentially traumatic for the patient and may lead to oophorectomy.

We describe how an Argyle trocar catheter inserted vaginally, may be used to treat pelvic abscess.

## PATIENTS

Three patients at risk of developing pelvic abscess underwent transvaginal ultrasound guided follicle aspiration under intravenous antibiotic cover. Two patients had endometriosis and one a history of chronic pelvic inflammatory disease. In addition, two patients had a history of pelvic abscesses after oocyte collection in other centers. All patients were admitted with pyrexia and pelvic pain within a week of UDFA. Ultrasound scans revealed echogenic cystic structure in the pelvis, suggestive of pelvic abscess.

The cause of the patients' pelvic disease and the number of egg collections and pelvic abscesses that they had are detailed in Table 1. A transvaginal ultrasound image of one of the pelvic abscesses is shown in Figure 1. Drainage of the pelvic abscesses was carried out as described. In all cases, microscopy of abscess fluid showed gram negative rods with *Escherichia coli* organisms sensitive to cefuroxime and gentamycin. Systemic antibiotics were administered post-operatively. All three patients made an uneventful recovery.

## TECHNIQUE

A general anesthetic was administered and the patient was placed in the lithotomy position. A bimanual examination was done to define the size, position and mobility of the pelvic abscess. The abscess was then identified using a transabdominal ultrasound transducer. The bladder volume was adjusted to give the best ultrasound image obtainable.

An Argyle trocar catheter (Sherwood Medical, Tullamore, Ireland), mounted with the introducer (Figure 2), was then guided into the vagina guarded by the operator's fingers. The tip of the catheter was then held against the pelvic mass. Using a rocking motion back and forth, the tip of the chest drain was then identified ultrasonically.

The direction of the catheter was adjusted using ultrasound guidance and then with a firm sharp thrust the trocar was pushed through the vaginal epithelium into the abscess cavity. Removal of the trocar (whilst gently pushing the drain into the abscess) was followed by the flow of pus, a sample of which was sent for bacteriological examination.

A speculum was then inserted into the vagina and the point of entry of the catheter identified. A single suture (Vicryl 1/0) was passed through the vaginal epithelium and the catheter was tied. The catheter was cut such that its end was just within the vagina. The catheter was left *in situ* for 2–3 days and then removed.

Correspondence: Mrs Geeta Nargund, Medical Director, Diana, Princess of Wales Centre for Reproductive Medicine, Academic Department of Obstetrics and Gynaecology, St George's Hospital Medical School, London SW17 0RE, UK

Received: 6-10-99 Revised: 25-4-00 Accepted: 12-7-00

Table 1 Details of patients treated with this technique

Patient	Predisposing factors for pelvic abscess	Total UDFA's	Egg collections followed by pelvic abscess	Mean diameter of abscess (cm)	Hospital stay after procedure (days)
A	Endometriosis	3	2	6.8	2
B	Endometriosis	3	2	8.0	4
C	Chronic PID	2	1	6.0	2

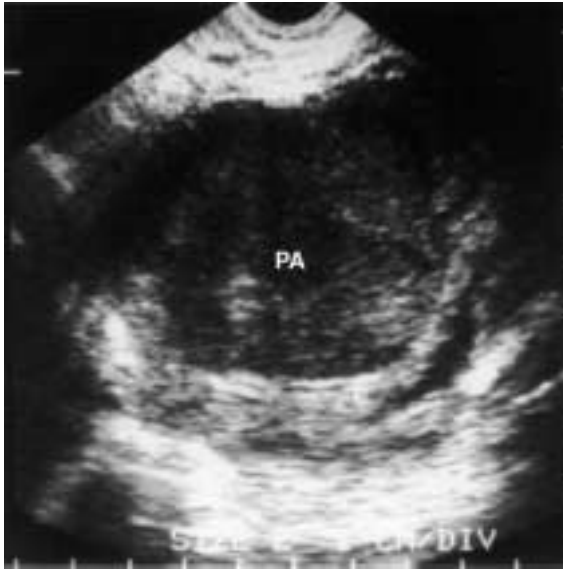

Figure 1 Transvaginal ultrasound image of a pelvic abscess (PA).




Figure 2 Argyle trocar catheter (12 Ch 23 cm). C, cannula; T, trocar.

## DISCUSSION

Apart from minor vaginal hemorrhage, pelvic infection is the most commonly encountered complication of transvaginal UDFA<sup>1</sup>. Possible causes of this complication include direct implantation of vaginal organisms, reactivation of latent infection in women with pelvic inflammatory disease and, following needle puncture of the bowel,

inoculation of the peritoneal cavity with pathogens. An earlier study of 1226 transabdominal transvesical UDFA's did not identify any infective complications<sup>4</sup>. This suggests that it is the passage of the needle through the vagina which leads to the infection, though previous pelvic inflammatory disease or endometriosis may predispose to this complication. Severe endometriosis with ovarian endometrioma seems to be a significant risk factor for development of pelvic abscess<sup>2</sup>. Postoperative pelvic abscess has been treated with antibiotics, needle aspiration<sup>3</sup> and drainage by either colpotomy<sup>5,6</sup> or laparotomy<sup>7</sup>. Prophylactic antibiotics do not seem to prevent this complication<sup>3</sup>.

Pelvic abscesses which developed following appendectomy and hemicolectomy have been drained under ultrasound guidance<sup>8</sup>. The authors described drainage of pelvic abscess using conventional catheter by an intraventional radiologist<sup>8</sup>. Ultrasound directed fine needle aspiration of pelvic abscess has also been described previously<sup>3</sup>. The authors partially refilled the abscess cavity with antibiotic solution after drainage. In this series involving 12 cases the procedure had to be repeated for up to six treatments in nine patients.

Although our paper specifically describes the management of pelvic abscess following transvaginal ultrasound directed follicle aspiration (UDFA), this technique can be used to drain pelvic abscess in other situations.

The main advantages of the use of a chest drain seem to be the ease of insertion and removal and the absence of catheter kinking. In our series the patient recovery was rapid and no repeat procedures were required. The patients subsequently underwent successful egg collections without pelvic infection.

We believe this technique adds another method for dealing with pelvic abscess after egg collection. The procedure seems to be safe and simple.

## REFERENCES

- Bennet S, Waterstone J, Cheng W, Parsons J. Complications of transvaginal ultrasound-directed follicle aspiration. A review of 2670 consecutive procedures. *J Assist Reprod Genetics* 1993; 10: 72-7
- Younis J, Ezra Y, Laufer N, Ohel G. Late manifestation of pelvic abscess following oocyte retrieval, for in vitro fertilisation, in patients with severe endometriosis and ovarian endometriomata. *J Assist Reprod Genet* 1997; 14: 343-6
- Nargund G, Parsons J. Infected endometriosis cysts secondary to oocyte aspiration for in vitro fertilisation (Letter to the eds). *Human Reprod* 1995; 10: 1555
- Riddle ANE, Sharma V, Mason BA, Fort NT, Pampiglione JS, Parsons J, Campbell S. Two years' experience of ultrasound directed oocyte retrieval. *Fertil Steril* 1987; 48: 454-8

5. Darling MR, Golan A, Rubin A. Colpotomy drainage of pelvic abscesses. *Acta Obstet Gynecol Scand* 1983; 62: 257-9
6. Rivlin ME, Golan A, Darling MR. Diffuse peritoneal sepsis associated with colpotomy drainage of pelvic abscess. *J Reprod Med* 1982; 27: 406-10
7. Benigo BB. Medical and surgical management of pelvic abscess. *Clin Obstet Gynecol Scand* 1981; 24: 1187-97
8. Noshier JL, Winhman HK, Needell GS. Transvaginal pelvic abscess drainage with US guidance. *Radiology* 1987; 165: 872-3